

MICOD 14/09/2023

Contributor: Dr. D. K. Singh

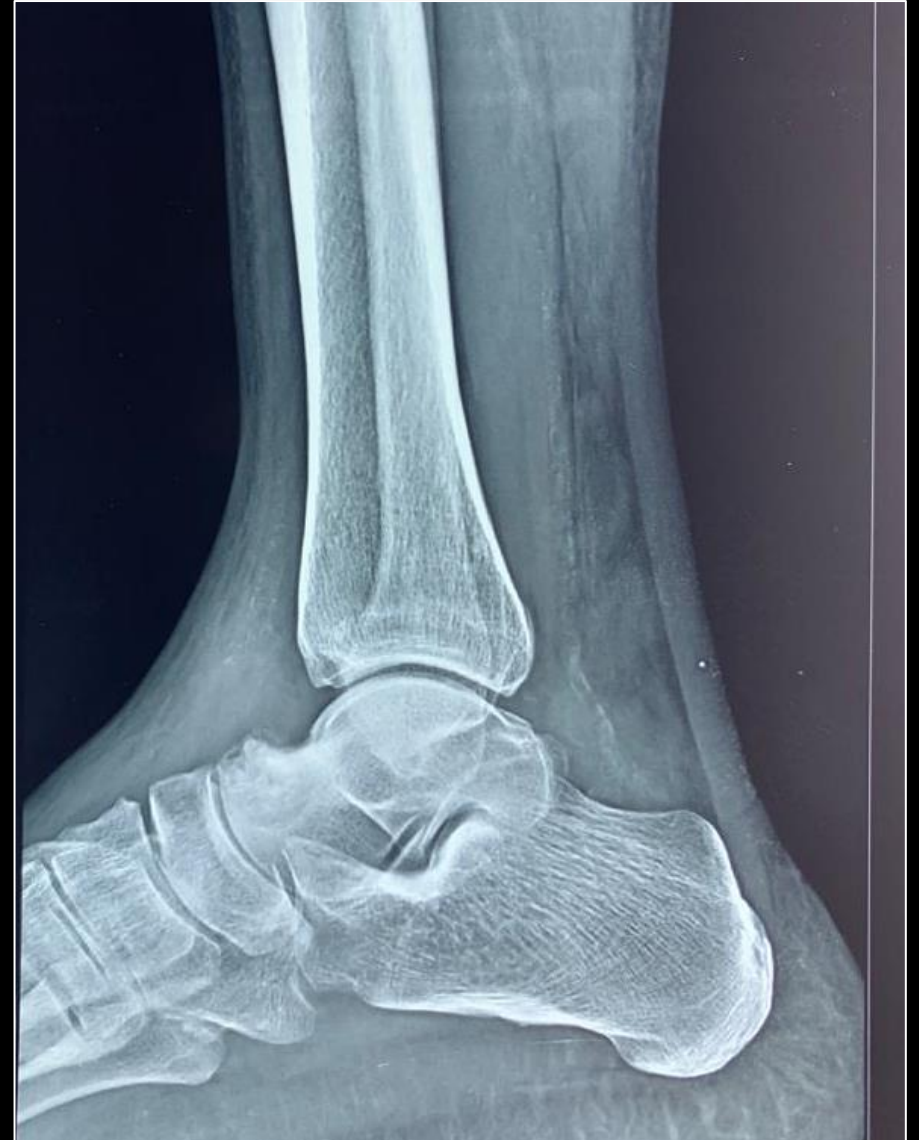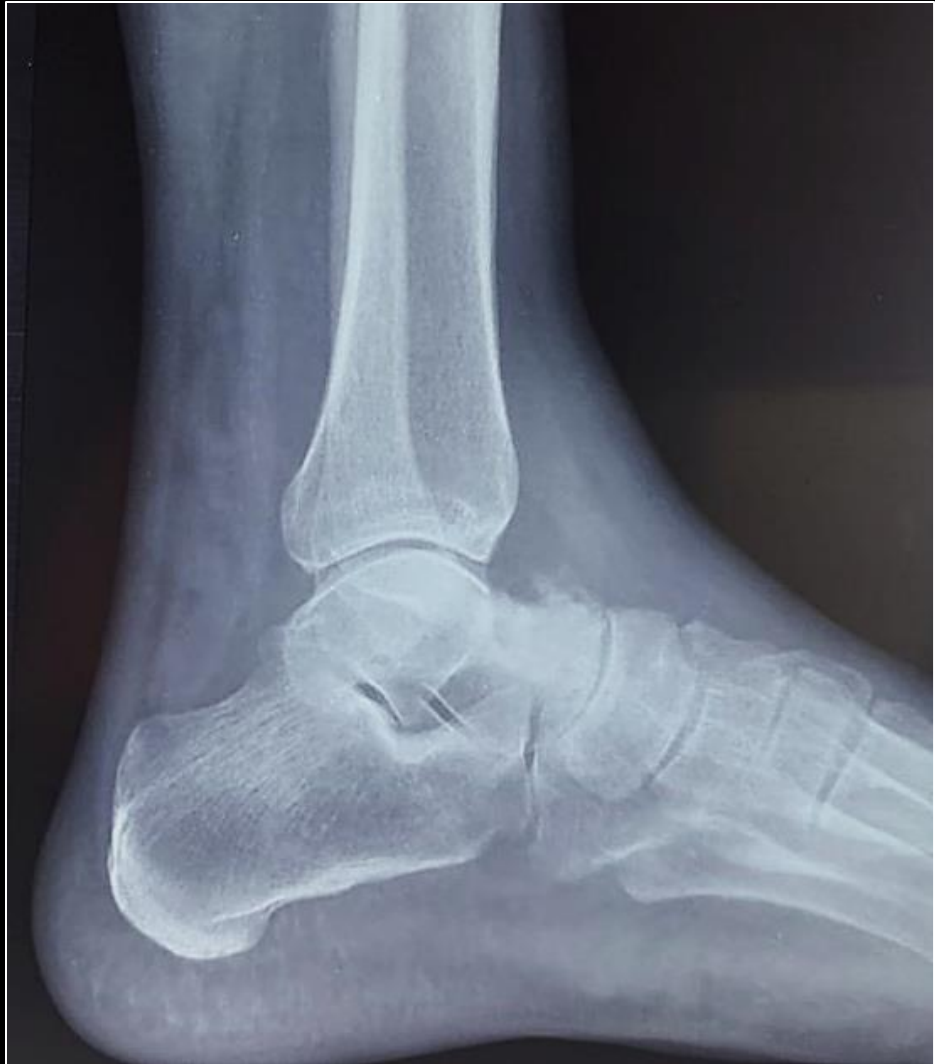MI-COD

MSS INDIA- Case Of the Day

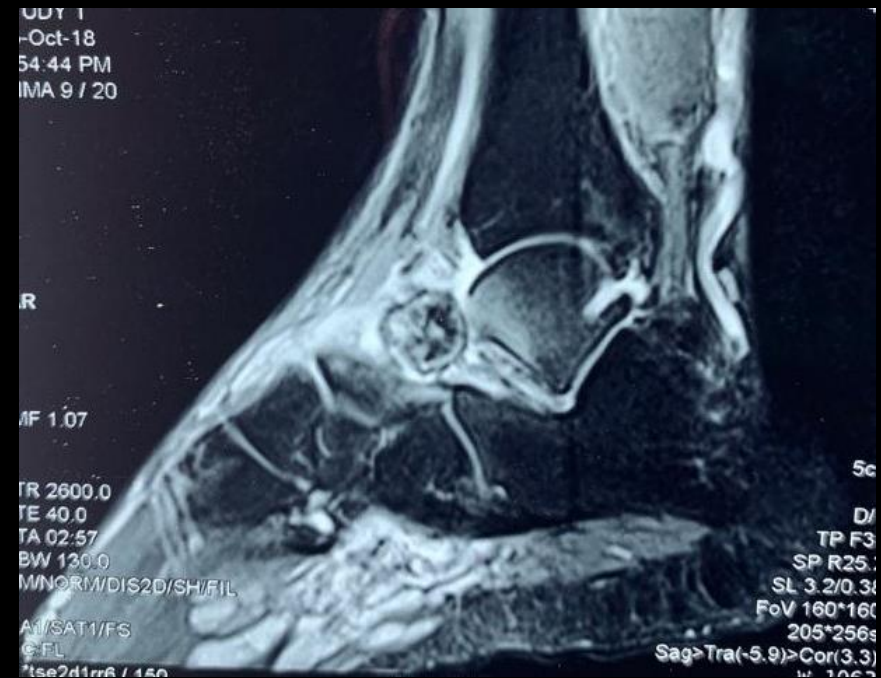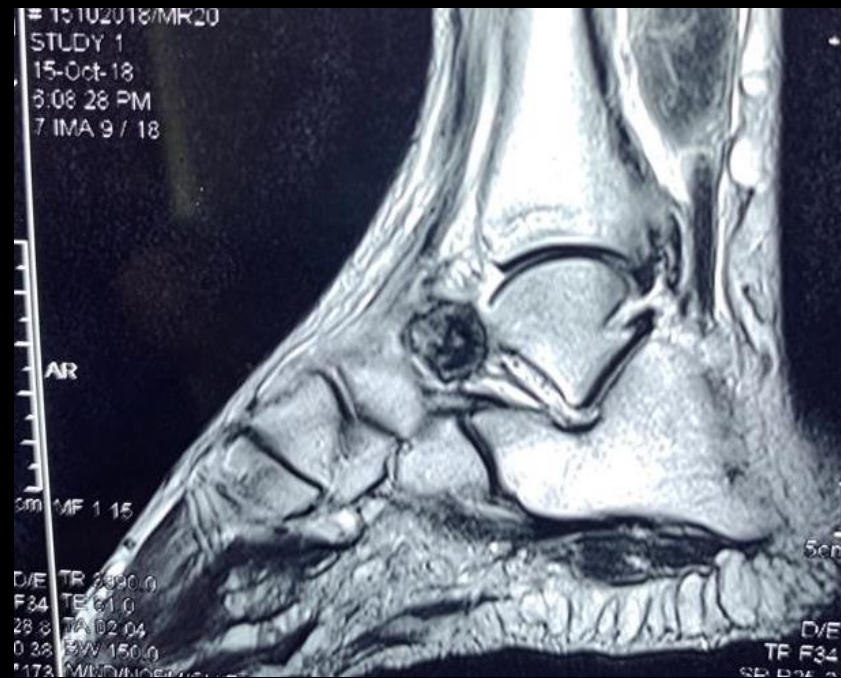
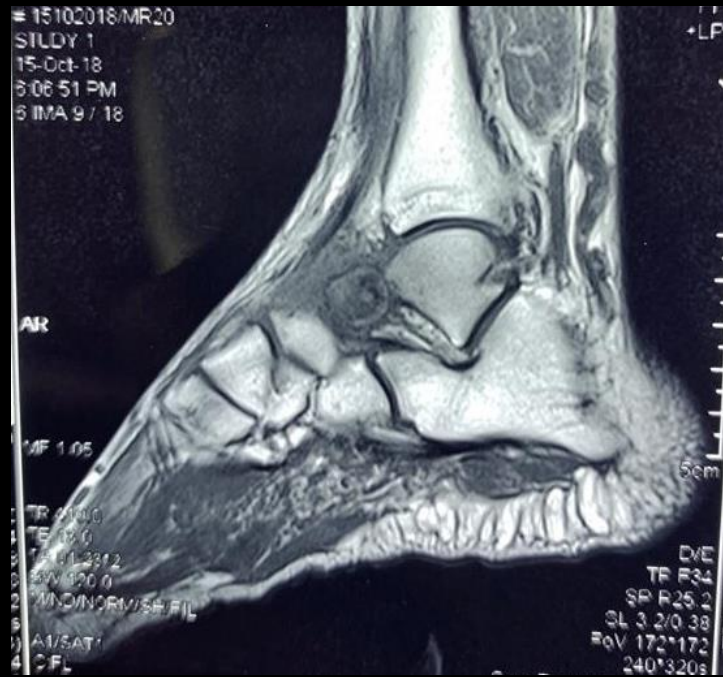


**27 year young male with pain and swelling on the dorsum of foot since 7 months**

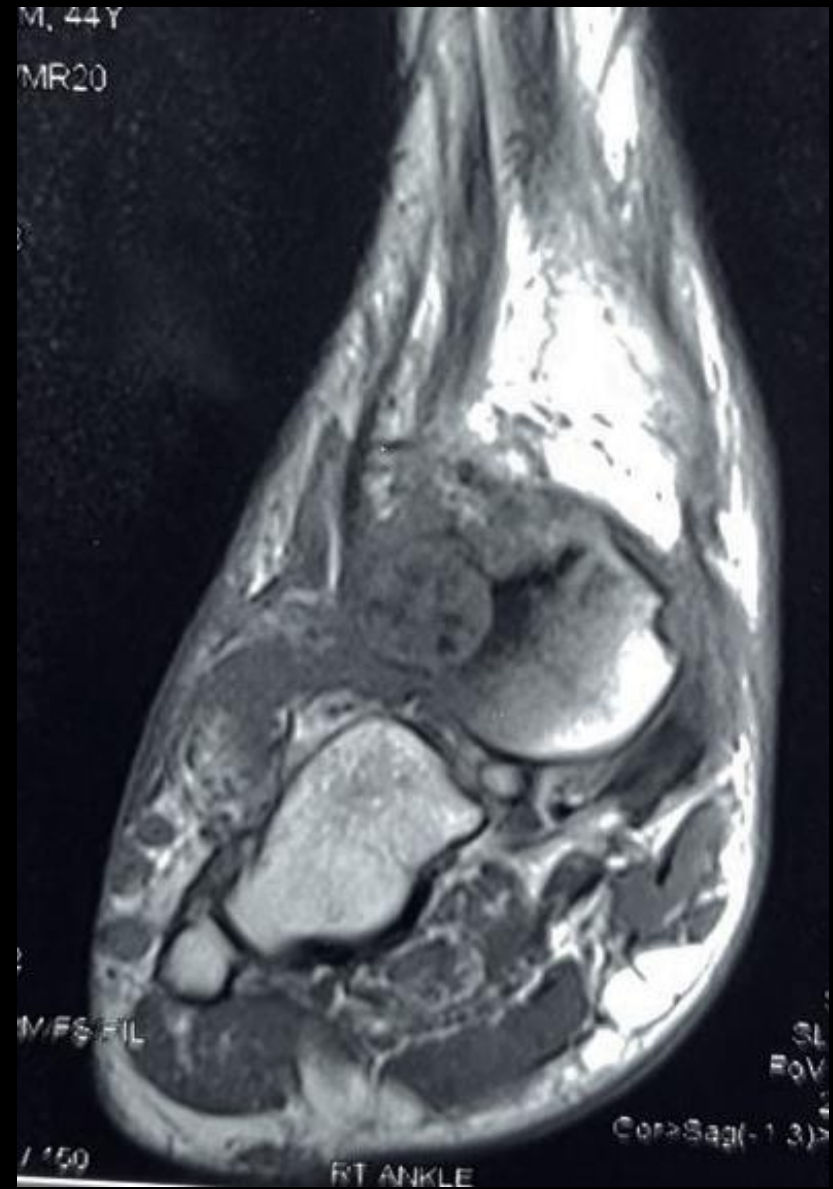
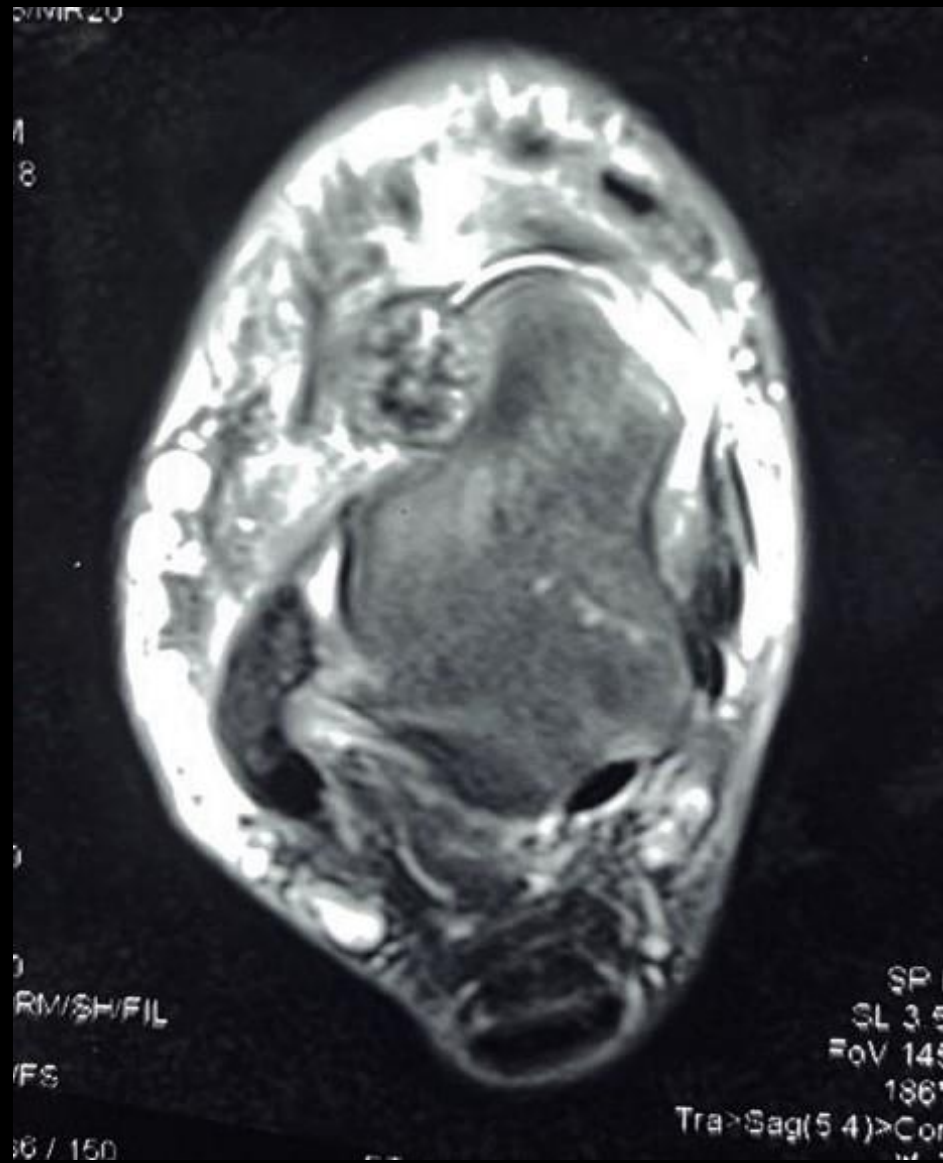
# Plain Radiograph



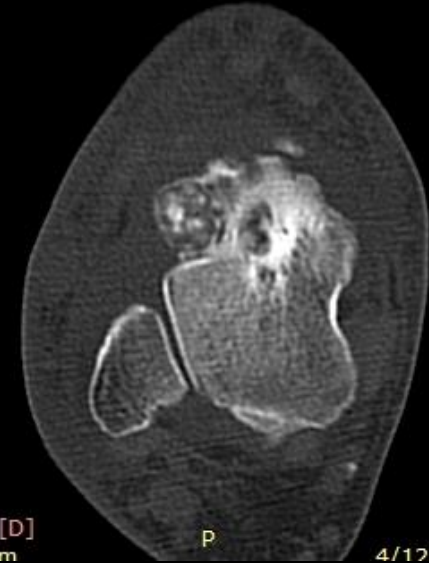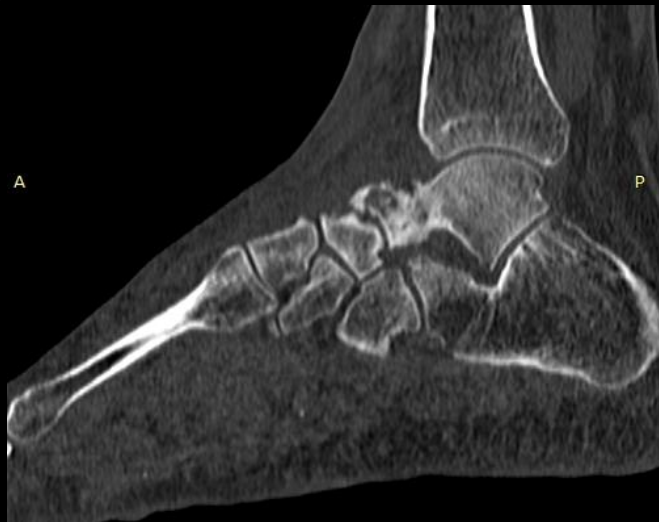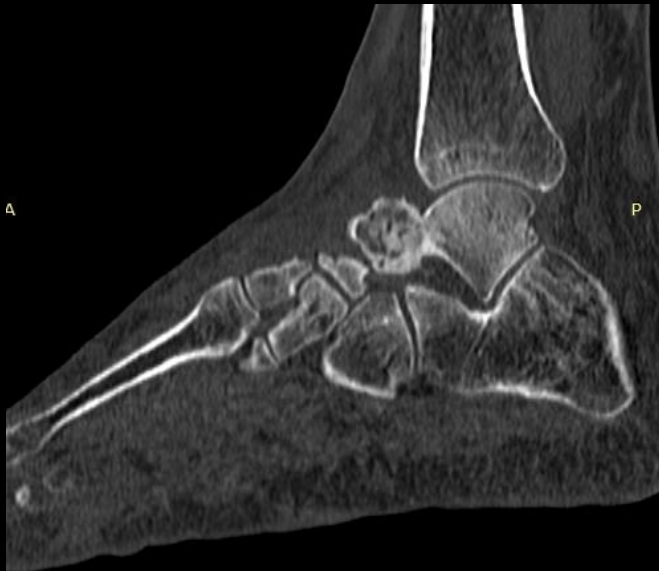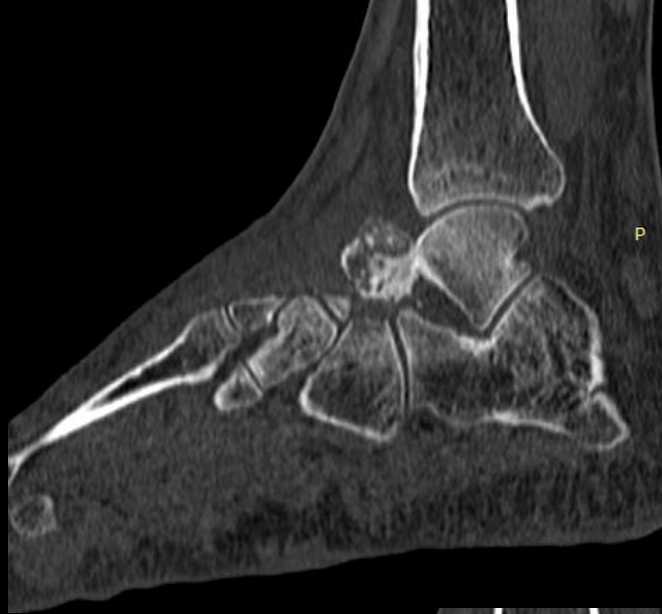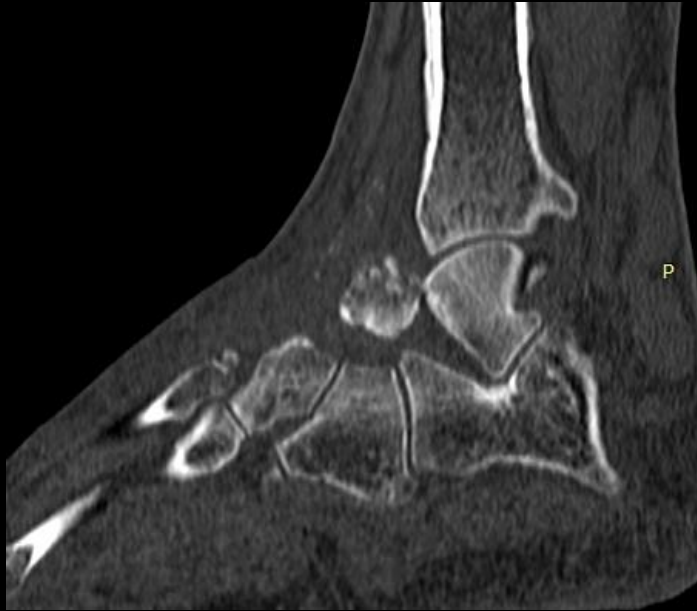# MRI



# MRI



# CT



1500 [D]  
38.9mm

71mA 120kV  
4/12/2019 10:43:41 AM