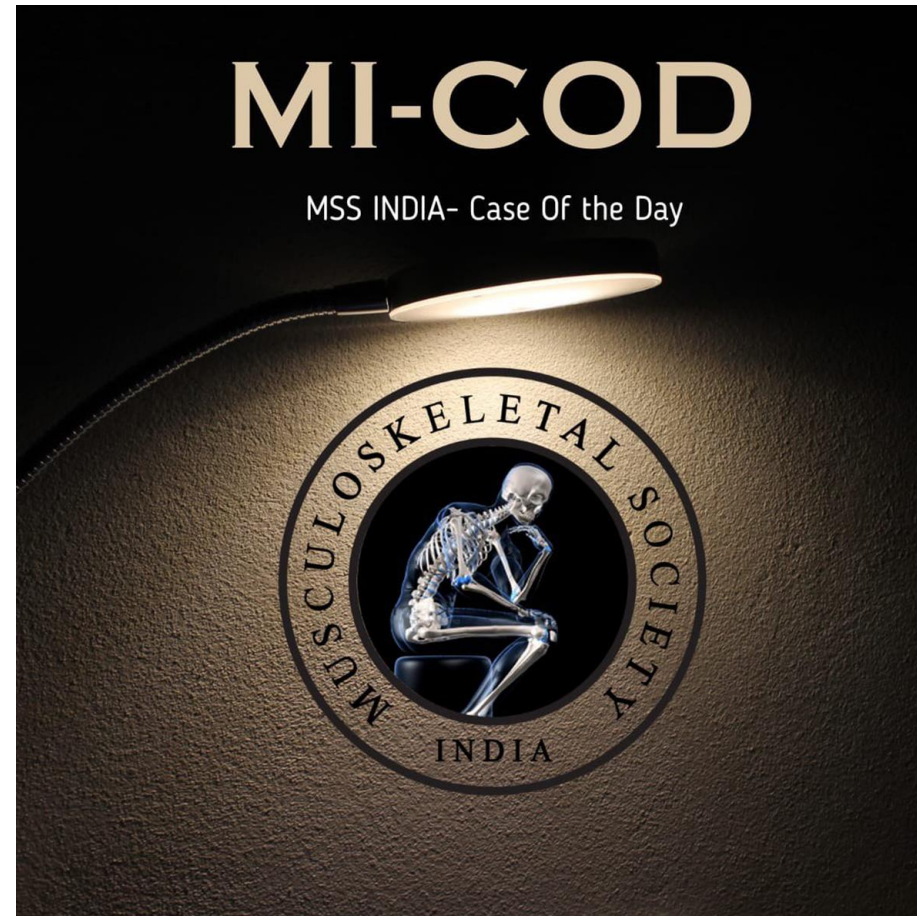


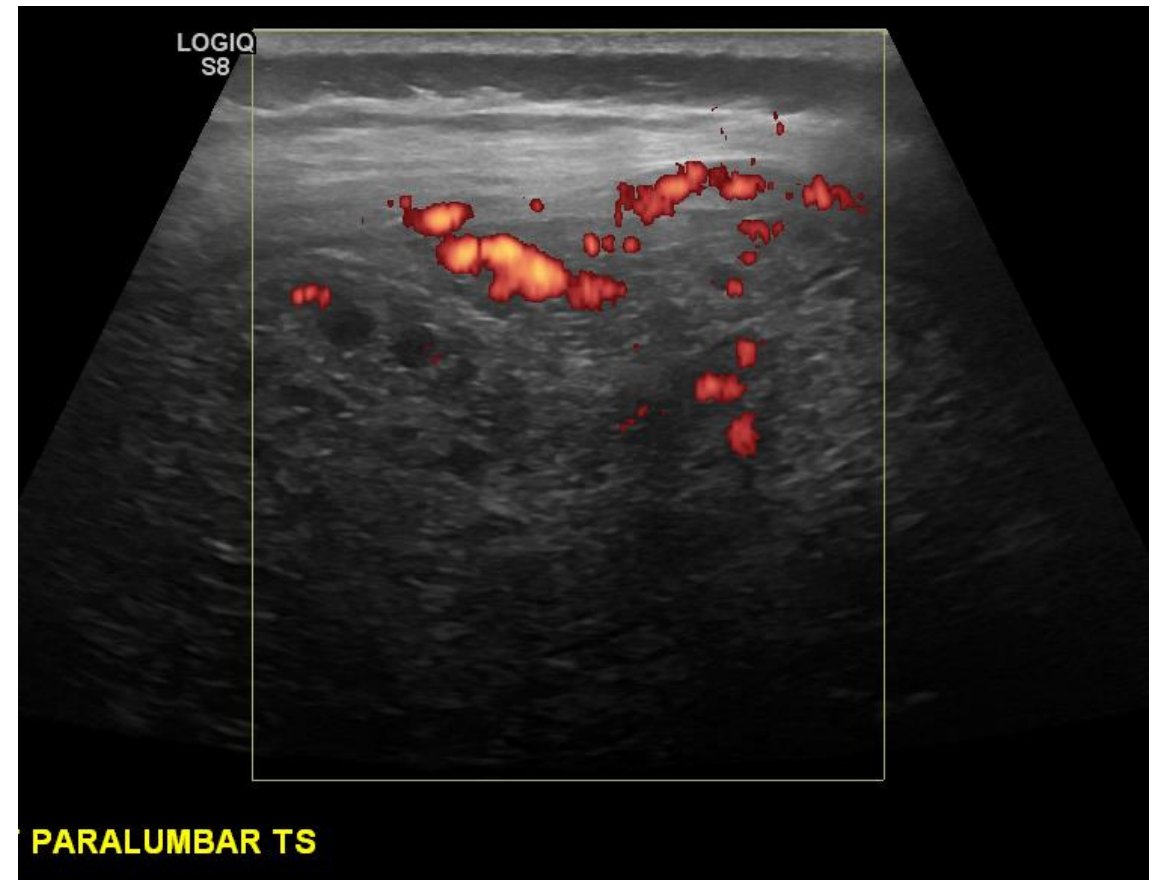
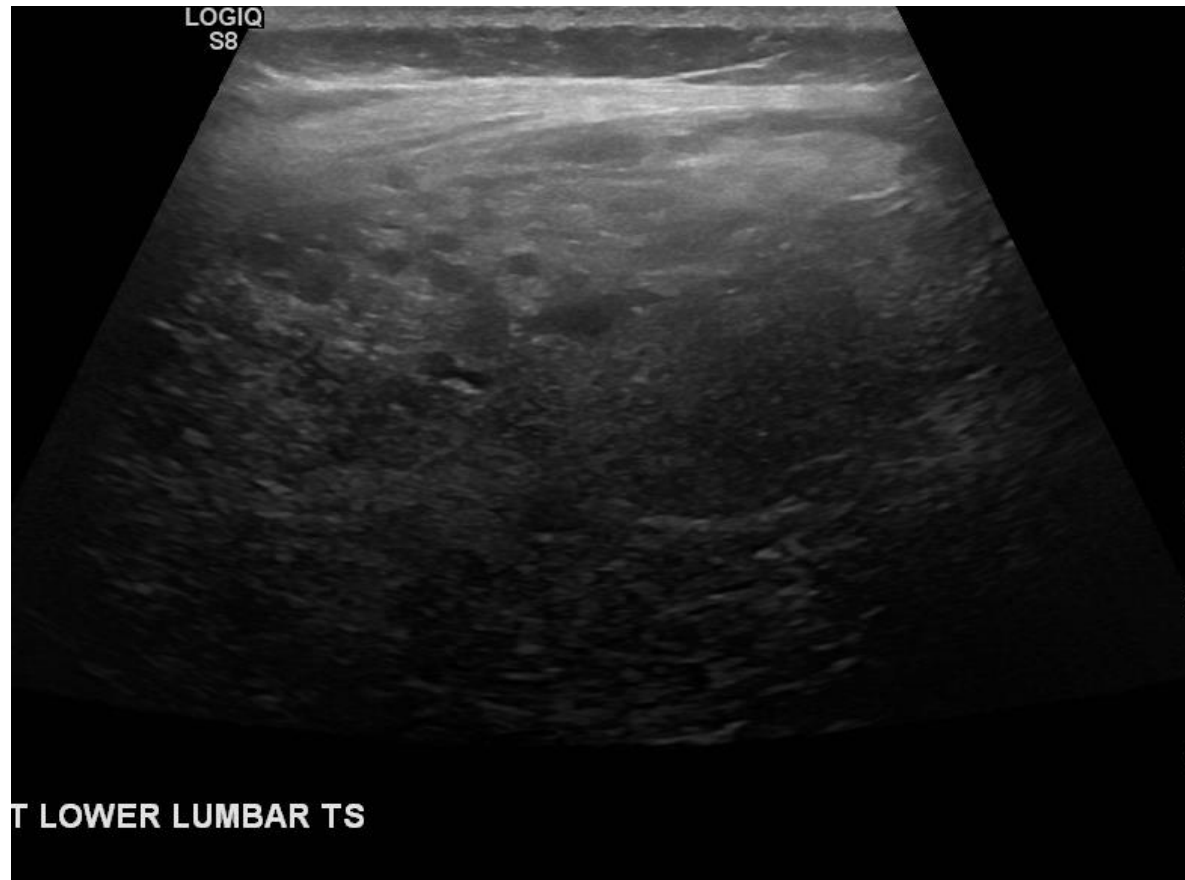MICOD -08/09/2023

Case contributor – Dr Harun Gupta

@mskteachingroom



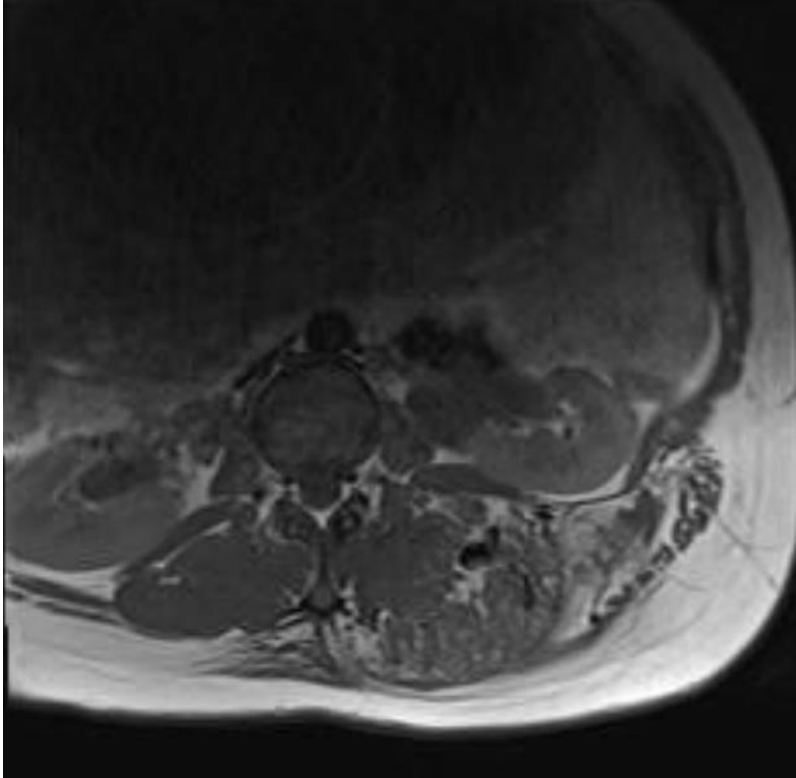
# 34 wk pregnant, lumbar region pain



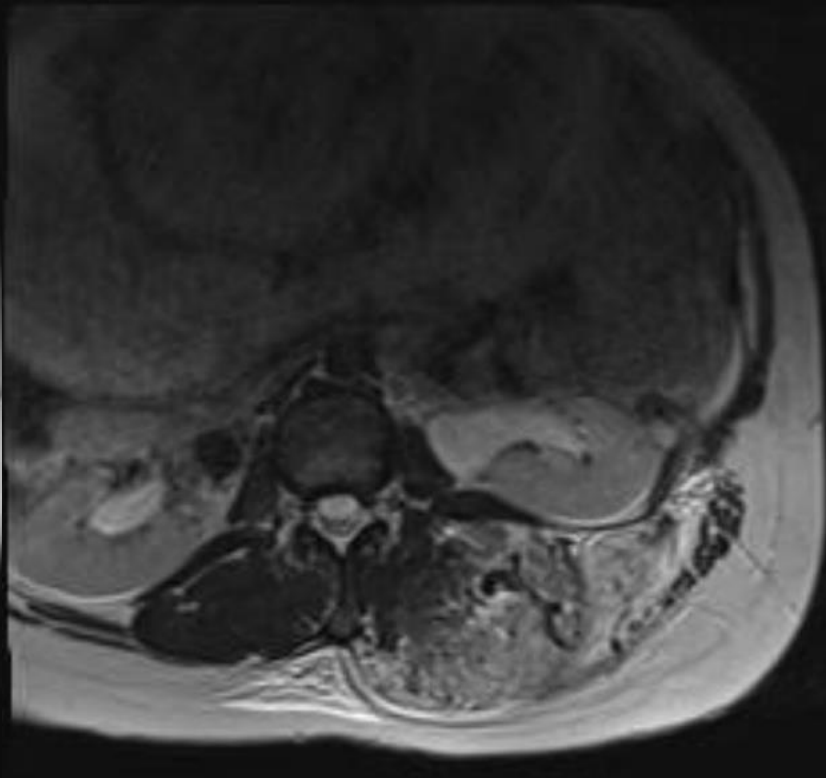
# 34 wk pregnant, lumbar region pain

- Link to Full Dicom case :

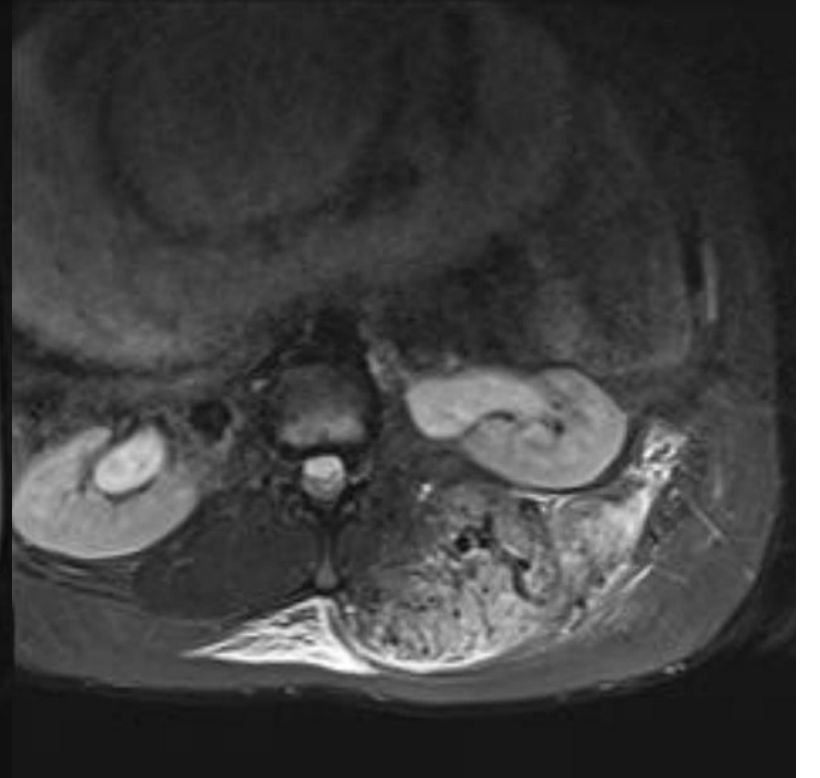
<https://www.cmrاد.com/cases/1525411776>



T1W



T2W



T2WFS

