

MICOD 14/09/2023

Contributor: Dr. D. K. Singh

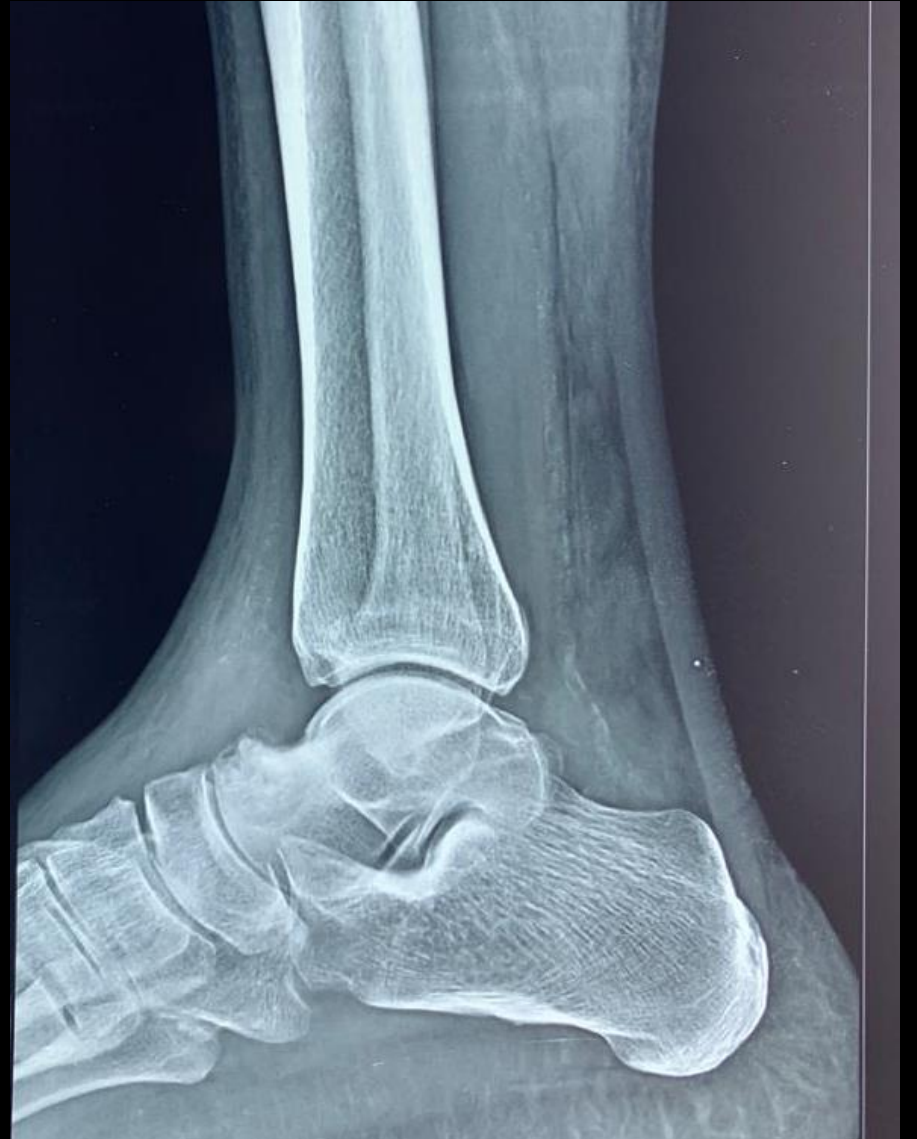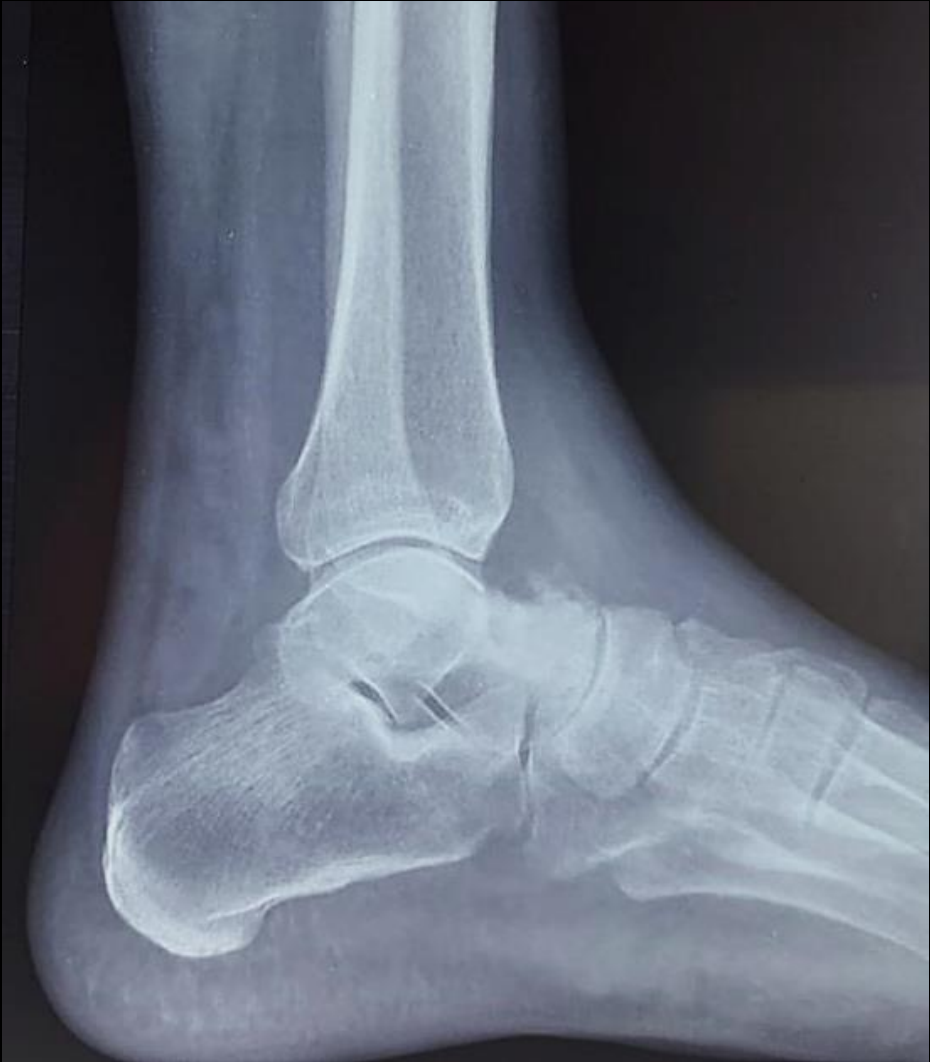MI-COD

MSS INDIA- Case Of the Day

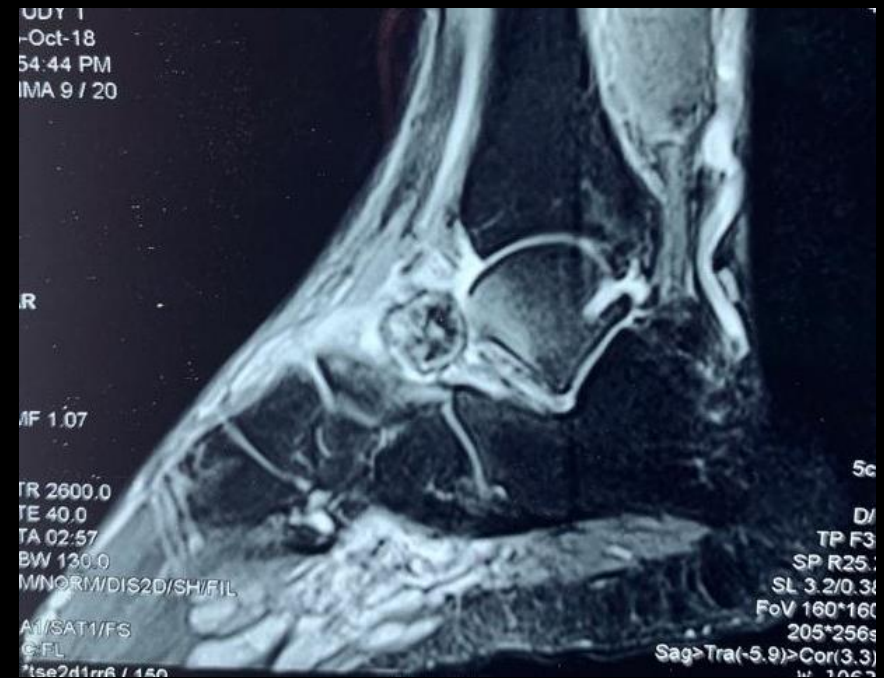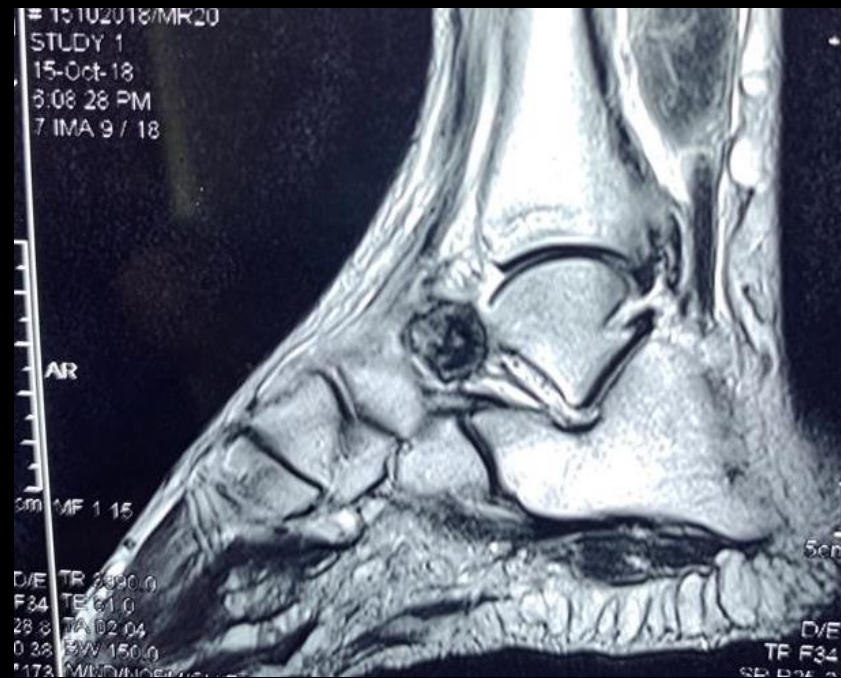
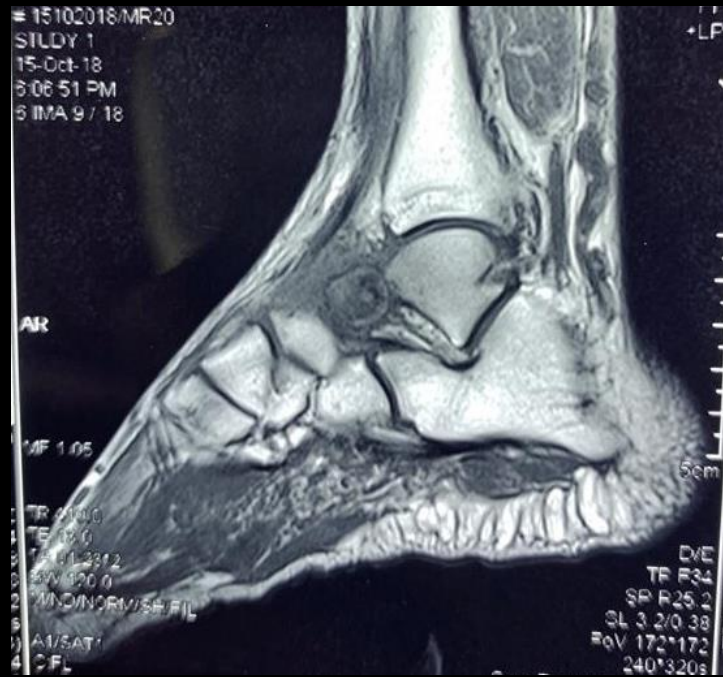


27 year young male with pain and swelling on the dorsum of foot since 7 months

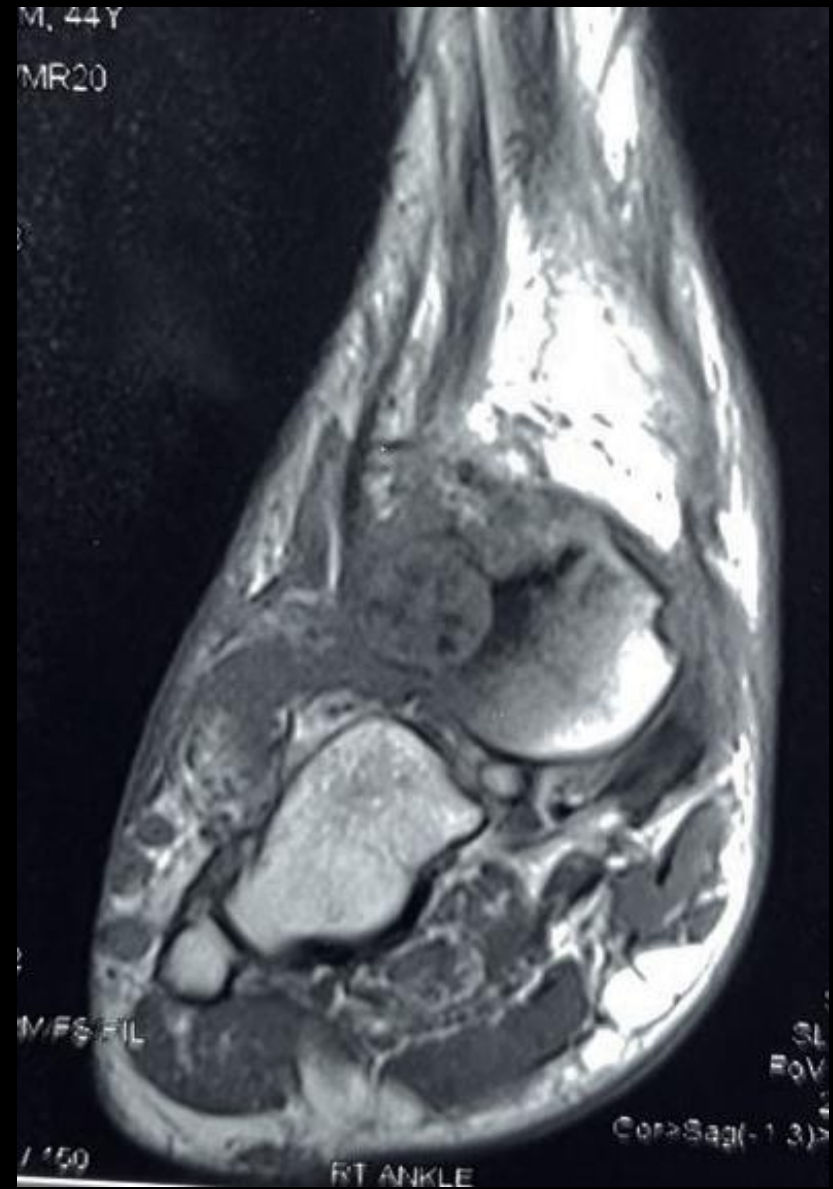
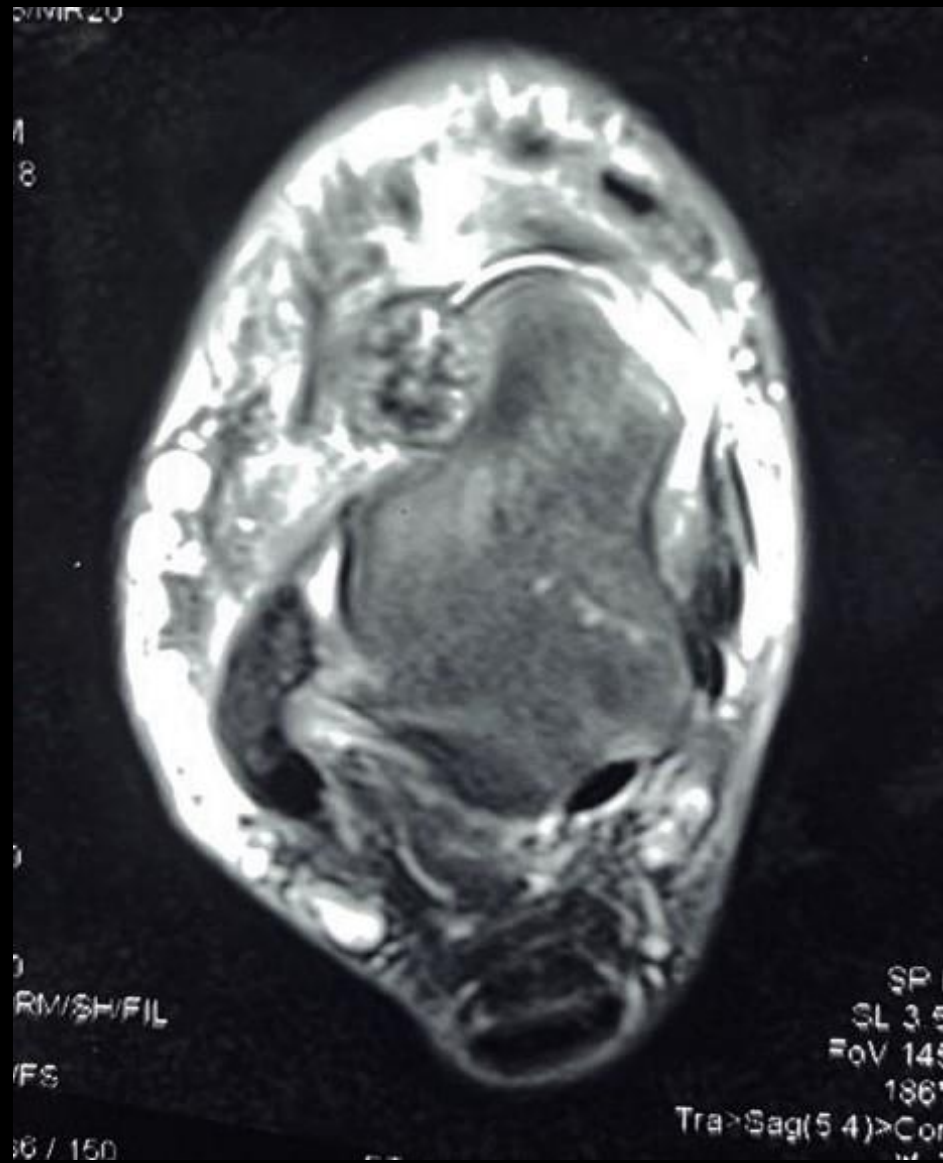
Plain Radiograph



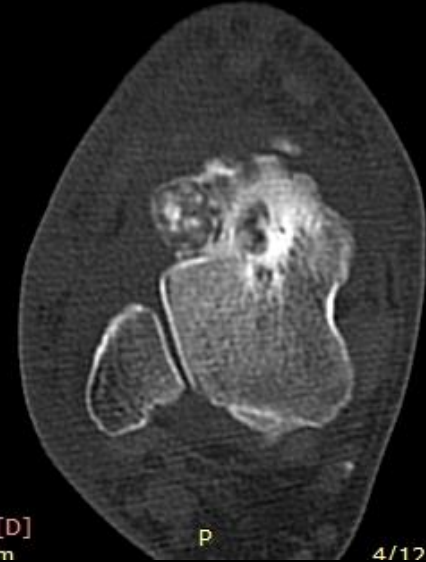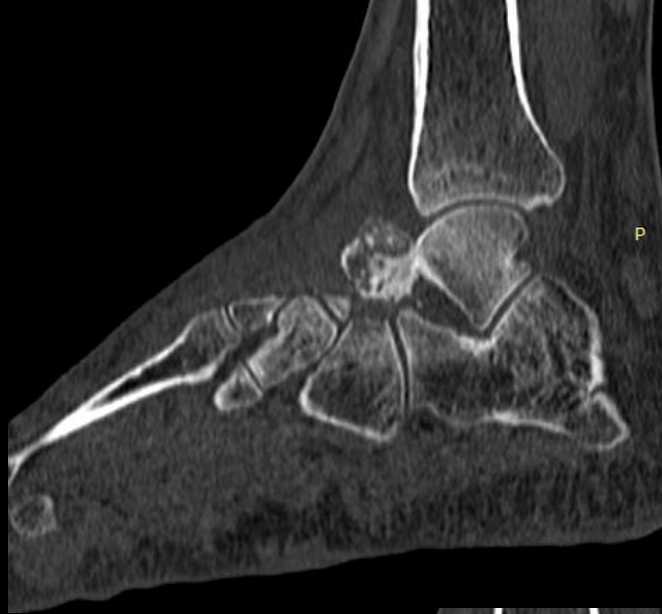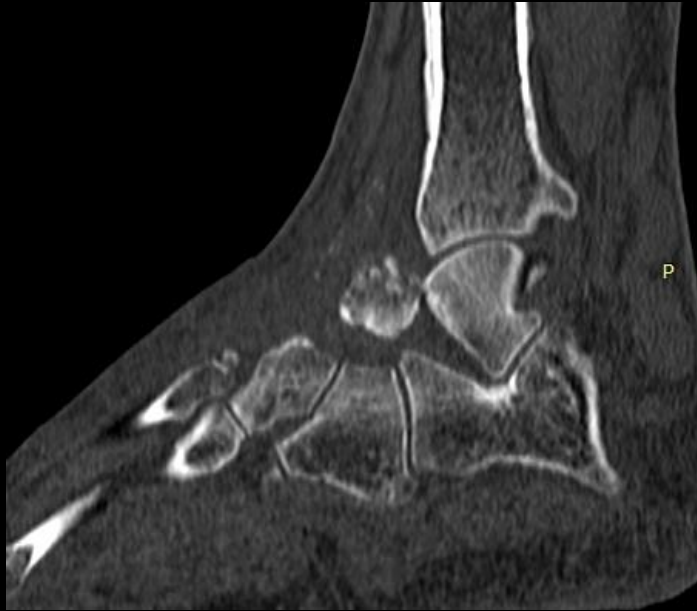MRI



MRI

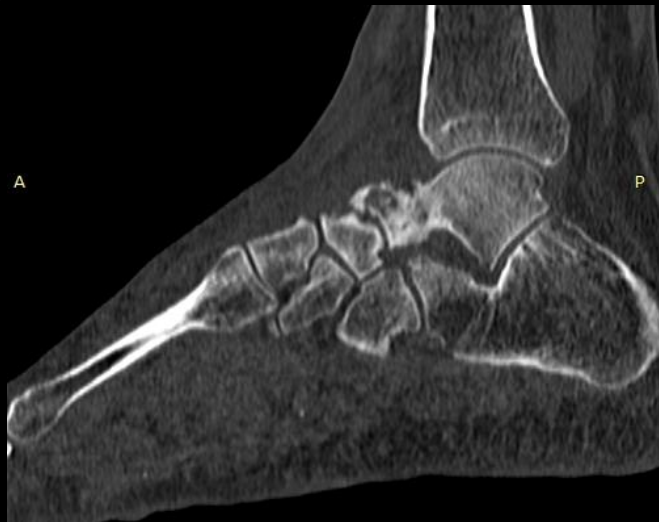
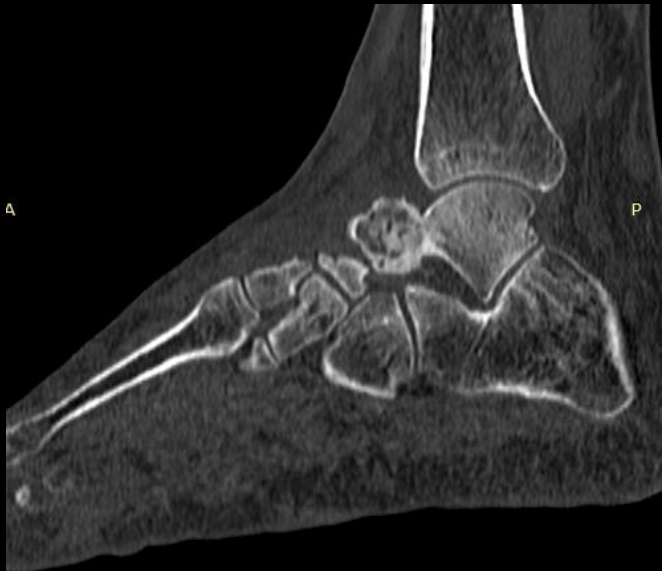
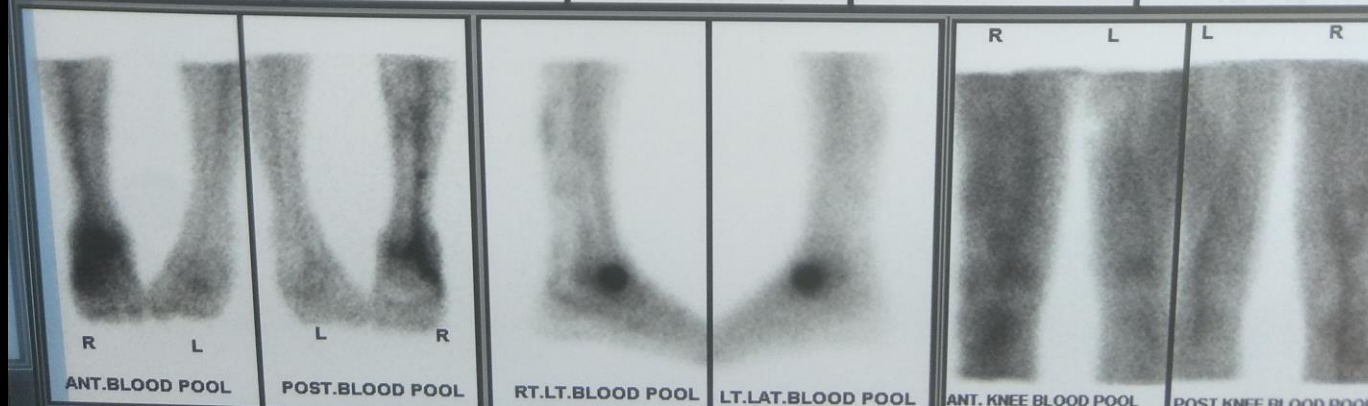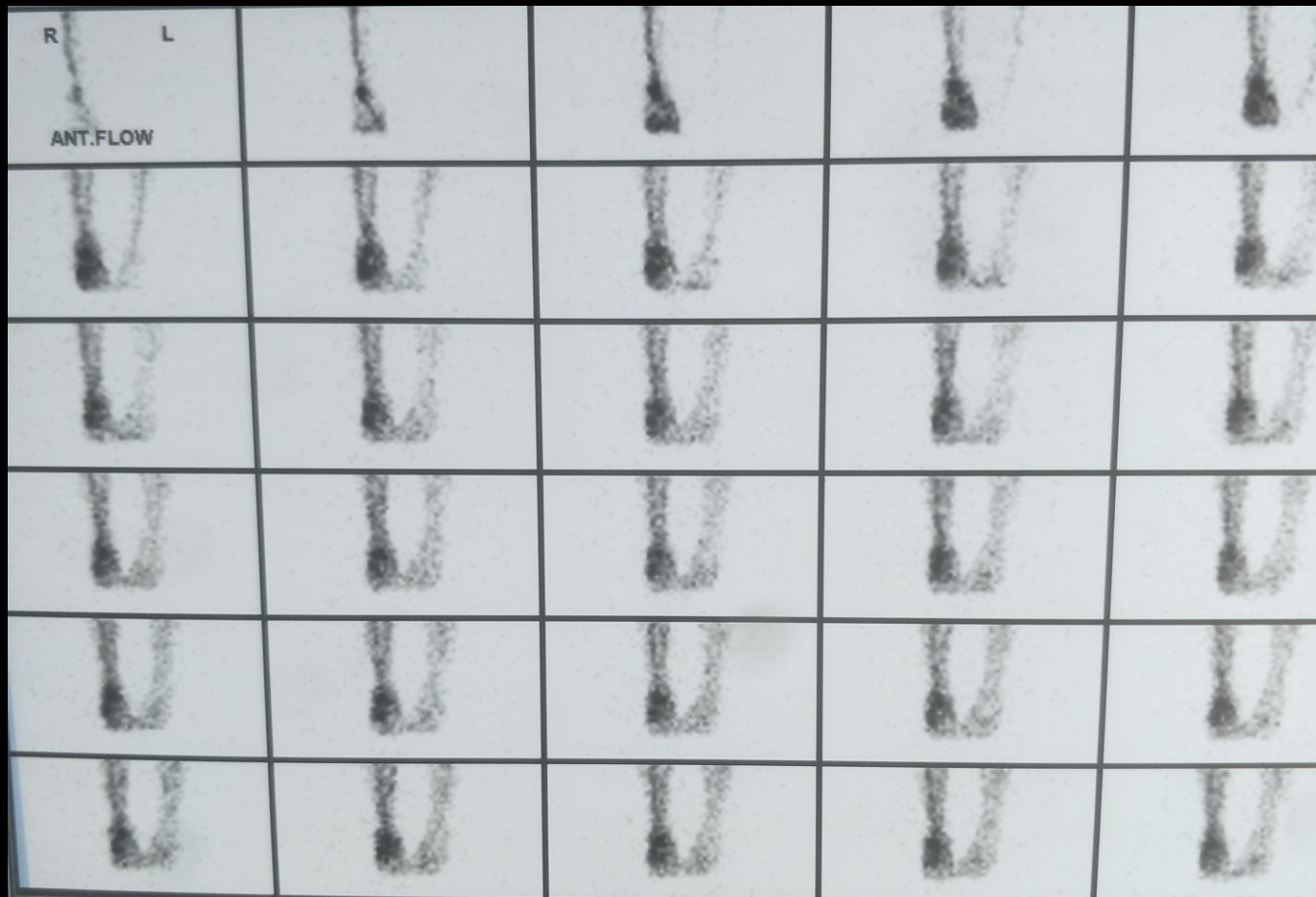CT



1500 [D]
38.9mm

71mA 120kV
4/12/2019 10:43:41 AM



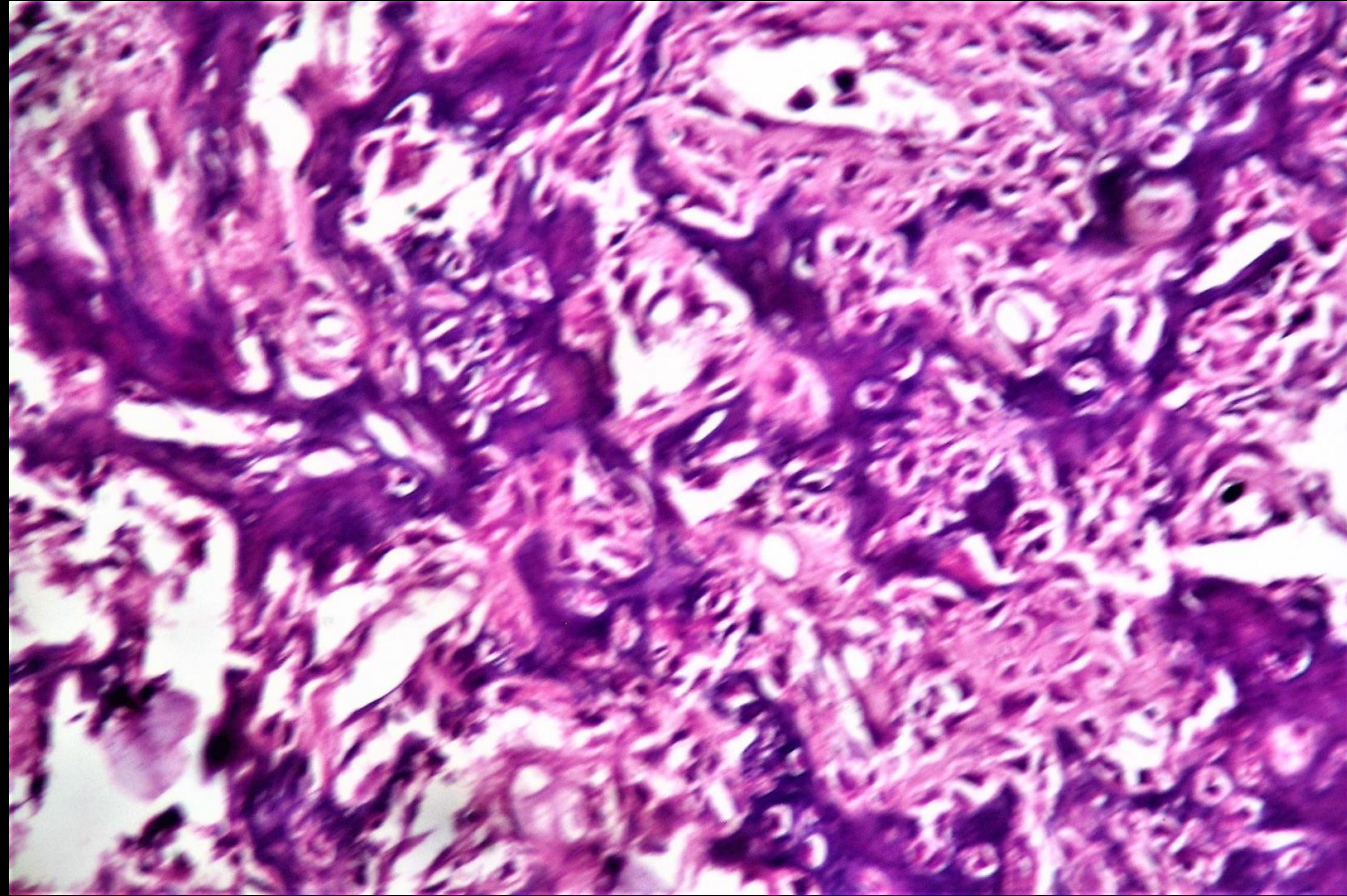


SW 1.50 m

Z 2.6



3 cm



Osteoblastoma

Agarwal S, Singh DK, Rustagi A, Krishna L, Talwar J. Osteoblastoma of Talus: A Diagnostic Dilemma. *Cureus*. 2020 Dec 2;12(12):e11838. doi: 10.7759/cureus.11838. PMID: 33409078; PMCID: PMC7781546.