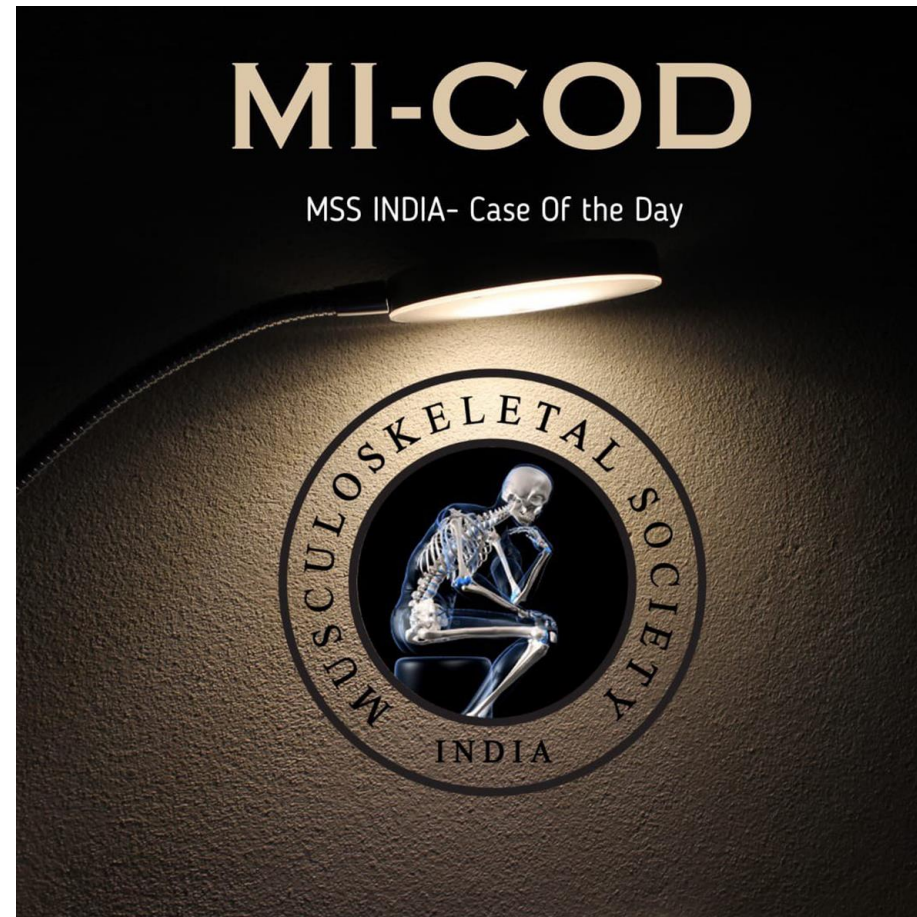


MICOD -08/09/2023

Case contributor – Dr Harun Gupta

@mskteachingroom



Diagnosis - Intramuscular haemangioma

- Learning points
 - In this case
 - Oedema seen around lesion and is due to engorgement related to pregnancy and enlarged feeding vessels also seen.
 - Typically should not have oedema around it
 - Appearances
 - Fat in the lesion (both on MRI and US)
 - Vascularity – linear type channels